



## AN ISOLATED FRACTURE OF THE STYLOID PROCESS OF THE TEMPORAL BONE: A RARE OCCURRENCE - A CASE REPORT

### Oral And Maxillofacial Surgery

**Girish V Chour**

Associate Professor Department Of Oral And Maxillofacial Surgery PMNM Dental College And Hospital Bagalkot - 587101

**Rashmi G Chour\***

Associate Professor Department Of Pedodontics PMNM Dental College And Hospital Bagalkot - 587101 \*Corresponding Author

### ABSTRACT

Styloid process is a long pointed cylindrical bone seen bilaterally on the temporal bone just below the auditory meatus. This process is about 25 mm in length. It acts as an important anchorage point for many muscles and ligaments which help in stabilising the mandible and assist in swallowing. Since the process is quite secure due to the attachments, an isolated traumatic fracture of the styloid process is a rare condition. An isolated fracture of the styloid process poses a challenge for diagnosis as the symptoms mimic temporomandibular joint disorder. This article is a case report of such an isolated traumatic fracture of the styloid process which was misdiagnosed as temporomandibular joint disorder.

### KEYWORDS

Styloid Process, Eagle's Syndrome, Fracture, Temporomandibular Joint Disorder.

### INTRODUCTION

Styloid process is a long pointed bony process seen bilaterally on the inferior part of petrous part of temporal bone just below the external auditory meatus. The average length of the process is about 25 mm ranging from 20mm to 30 mm. It provides attachments for many ligaments and muscles like the stylohyoid ligament, the stylohyoid, stylopharyngeus, and styloglossus muscles. Through these structures this process helps in movements of tongue, pharynx, larynx, hyoid bone and mandible.

Even though the structure looks fragile, it is well protected by the attachments to it and trauma to the styloid process is a rare situation. In some cases of polytrauma, the styloid process may get fractured; but an isolated fracture of the styloid process is extremely rare.

Because of this rare condition, the diagnosis of the fracture becomes extremely difficult as the symptoms mimic temporomandibular disorders. Hence thorough knowledge of the anatomy and a comprehensive knowledge of the signs and symptoms makes it possible to diagnose and treat the condition.

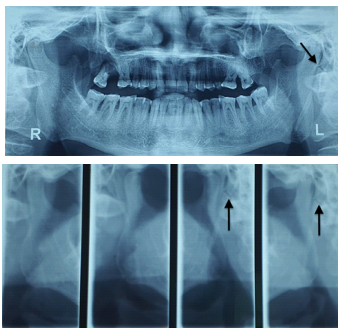
### CASE REPORT

A 45 year old male patient walked in the department complaining of ringing sensation in the left ear and pain while swallowing.

He was suffering from this problem for 2 months. He has since visited an Otolaryngologist for the same with no relief. Since his symptoms mimicked Temporomandibular joint disorders (TMD) he was misdiagnosed and treated for the same.

When asked, the patient gave a history of biting on a large piece of arecanut due to which he had severe toothache and then later on the following day he noticed a small diffuse swelling below the left ear lobe and pain on swallowing along with tinnitus in the left ear. On examination the inspeactory findings could be confirmed.

For further investigation, radiographs were advised, a panoramic radiograph (OPG) and Temporomandibular joint (TMJ) view were taken which revealed fractured styloid process on the left side.



The patient was explained about the condition and conservative treatment was advised with anti-inflammatory drugs to reduce the pain and swelling. After 3 months of follow up the patient was without any symptoms and complaints.

### CONCLUSION

An isolated fracture of the styloid process in a non-syndromic patient is a very rare condition. Due to this rare nature of the case it is difficult to diagnose as the symptoms mimic Temporomandibular Joint Disorders (TMD), as was the case in this patient who was being treated for TMD without any success.

The key to diagnosing such cases is a keen eye on the history given by the patient and a thorough knowledge of the anatomy which will help in prompt diagnosis and proper treatment.

### REFERENCES

- Orlik K, Griffin GD, Zoumerakis E. Unilateral neck pain: a case of Eagle syndrome with associated nontraumatic styloid fracture. *Am J Emerg Med.* 2014;32(1):112 e1-2.
- Dubey KN, Bajaj A, Kumar I. Fracture of the styloid process associated with the mandible fracture. *Contemp Clin Dent.* 2013;4(1):116-8.
- Thoenissen P, Bittermann G, Schmelzeisen R, Oshima T, Fretwurst T. Eagle's syndrome-A non-perceived differential diagnosis of temporomandibular disorder. *Int J Surg Case Rep.* 2015;15:123-6
- Kermani H, Dehghani N, Aghdashi F, Esmaeelinejad M. Nonsyndromic Isolated Temporal Bone Styloid Process Fracture. *Trauma Mon.* 2016 Feb 6;21(1):e24395.
- Atsu SS, Tekdemir I, Elhan A. The coexistence of temporomandibular disorders and styloid process fracture: a clinical report. *J Prosthet Dent.* 2006 Jun;95(6):417-20.
- Mayrink G, Figueiredo EP, Sato FR, Moreira RW. Cervicofacial pain associated with Eagle's syndrome misdiagnosed as trigeminal neuralgia. *Oral Maxillofac Surg.* 2012 Jun;16(2):207-10.